



PRESENTING CLINICAL SIGNS

History: Grade 4-5/6 murmur. Had heartworm disease when younger. Receiving prednisone.

DATE

12/22/22

ECHOCARDIOGRAPHIC FINDINGS

2D, M-mode, and Doppler study.

PERFORMED BY:

Kelly Vazquez

INTERPRETED BY

Keith Blass, DVM,
MS, DACVIM
(Cardiology)

There is mild to moderate left atrial dilation. The mitral valve leaflets are thickened and exhibit systolic prolapse. There is Doppler evidence of mitral regurgitation present. There is mild left ventricular dilation. Left ventricular systolic function is normal. The aorta and aortic valve are normal. Right atrial and right ventricular dimensions are normal. The tricuspid valve leaflets are mildly thickened, and there is Doppler evidence of tricuspid regurgitation present. TR velocity is consistent with the presence of very mild pulmonary hypertension (PG 32.7 mmHg). The pulmonary artery and pulmonic valve are normal. No shunting lesions are visualized. No heartworms are visualized. No pericardial effusion or cardiac masses are seen.

LA - 52.2 mm
LVIDd - 48.3 mm
LVIDs - 28.8 mm
FS - 40.4%
RA - 30.3 mm
LVOT - 1.44 m/s
RVOT - 0.94 m/s
TR - 2.86 m/s

PATIENT

Coben Beucler

SPECIES

Canine

ASSESSMENT/RECOMMENDATIONS

Degenerative mitral and tricuspid valve disease
Pulmonary hypertension

BREED

Hound Mix

This examination demonstrates regurgitation of blood across Coben's mitral and tricuspid valves resulting from degenerative valve disease. Coben's tricuspid valve disease is mild, and appears to be well-compensated. His mitral valve disease is more advanced, as Coben has mild to moderate secondary dilation of his left atrium and mild dilation of his left ventricle, as well as very mild secondary pulmonary hypertension. Coben's mitral valve disease is still compensated, however, he could become at risk for the development of clinical signs secondary to it, such as coughing, exercise intolerance, syncope, and labored breathing, if his disease progresses much further.

SEX

MN

I recommend starting Coben on pimobendan (7.5 mg BID), as this medication should help to slow the progression of his valvular diseases.

AGE

11 y

A recheck echocardiogram is recommended in ~6 months. Thoracic radiographs are recommended if Coben experiences respiratory clinical signs.

WEIGHT

68.8 lb

HOSPITAL NAME

Cresskill AH

REFERRING VET

Dr. Khodari



DATE

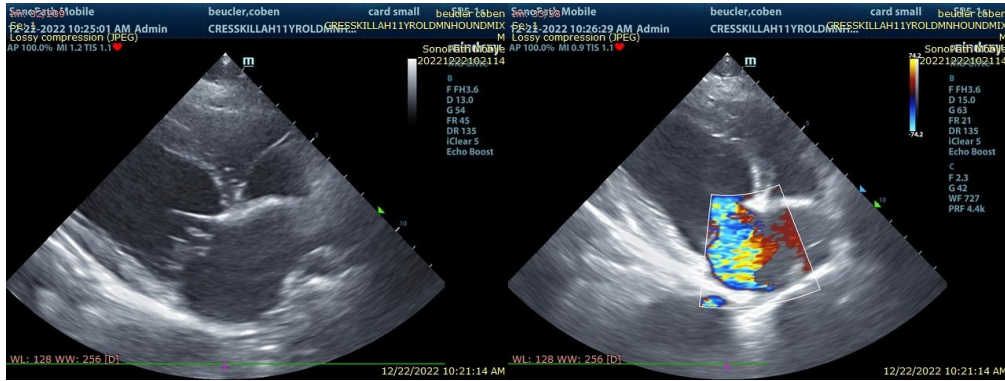
12/22/22

PERFORMED BY:

Kelly Vazquez

INTERPRETED BY

Keith Blass, DVM,
MS, DACVIM
(Cardiology)



The information and recommendations provided are based on the images presented by the referring veterinarian. No evaluation can be communicated regarding pathology that was not visible in the image/video clips provided.

Thank you for this referral. If the clinical or image interpretation does not parallel your findings or if I can be of any further assistance please contact me.

PATIENT

Coben Beucler

Keith Blass, DVM, MS, DACVIM (Cardiology)
KeithBlass@gmail.com
631-804-5754

SPECIES

Canine

BREED

Hound Mix

SEX

MN

AGE

11 y

WEIGHT

68.8 lb

HOSPITAL NAME

Cresskill AH

REFERRING VET

Dr. Khodari